

Superior (cephalic)

Posterior (dorsal)

Anterior (ventral)

Proximal

Distal

Deep

Proximal

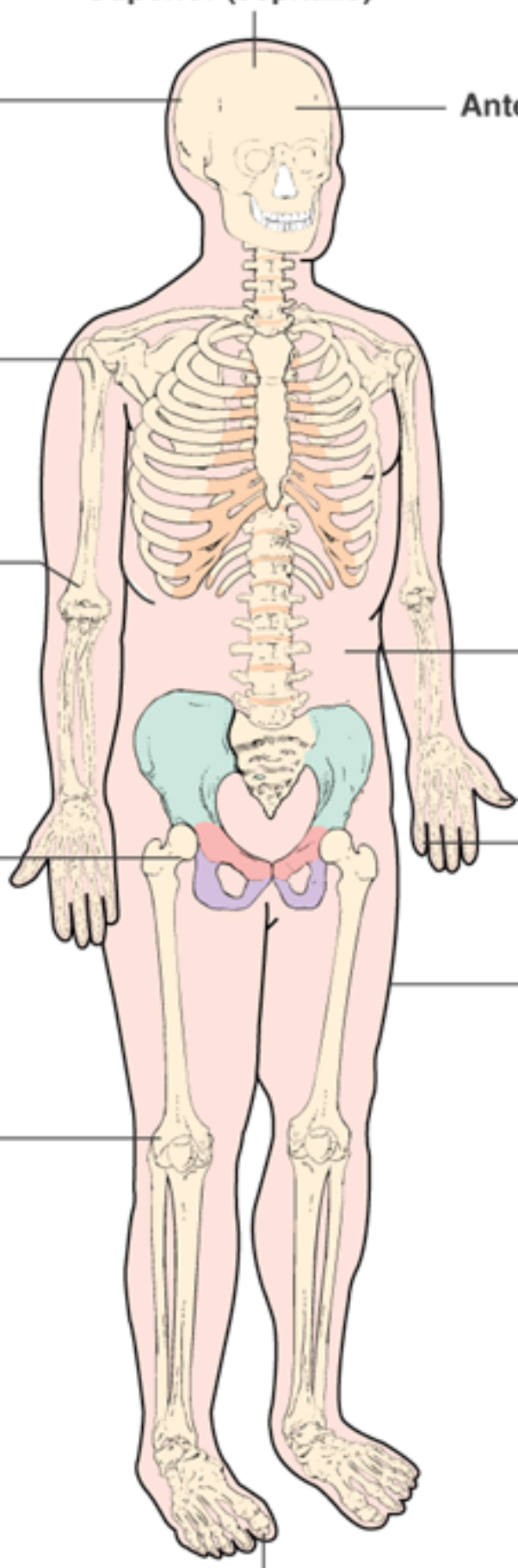
Lateral (thumb)

Medial (5th finger)

Superficial

Distal

Inferior (caudal)



Positional and directional terms.